

Veterinary Diagnostic Laboratory

Iowa State University
College of Veterinary Medicine
Ames, Iowa 50011-1134

Phone: 515-294-1950

Fax: 515-294-3564

Preliminary Report

Report Date: 03/24/2017 8:35 AM

Dr Bianca Zaffarano
Lloyd Veterinary Medical Center
1732 Vet Med

Ames, IA 50011

Owner : Joe Monahan
Division :

Site : Joe Monahan
711 V Ave
Boone, IA 50036

Premises ID# :

Lot/Group ID :

Source/Flow ID :

Reference:

Diagnostician: Rachel J Derscheid

Client Phone: 1-515-294-4900

Client Fax: 1-515-294-7520

Client Account#: 201-00-25-00-1100

Date Received: 3/21/2017

Sample Taken:

Preliminary Report:

Species: Snake

Breed: Snake

Sex:

Previous Case:

Farm Type:

Animal ID(s): A, Florida Water Snake

Age: 8 Months

Weight:

Received:

1 Dead

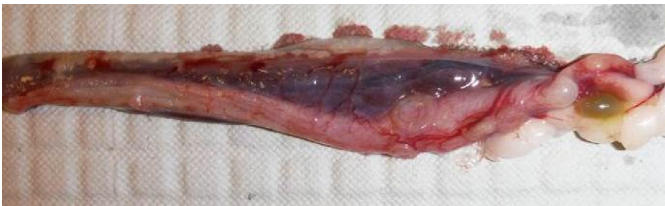Reason:

History: 8-month-old Florida green water snake (*Nerodia floridana*), one of a group of 9 purchased as a group. Each snake is housed in an individual container in isolation. Initial symptoms of snake fungal disease, including white subcorneal pustules and increased shedding, have been reversed. This snake was found dead on 20-March, and put in refrigerator since. Their diet has included bait minnows, which have a thiamine these, and can lead to thiamine deficiency

Gross Pathology:

There are 4 coiled nematodes, approximately 1 mm diameter with coils approximately 7 to 9 mm diameter. Lungs are slightly nodular and off white. There is adequate to abundant fat in the coelom.

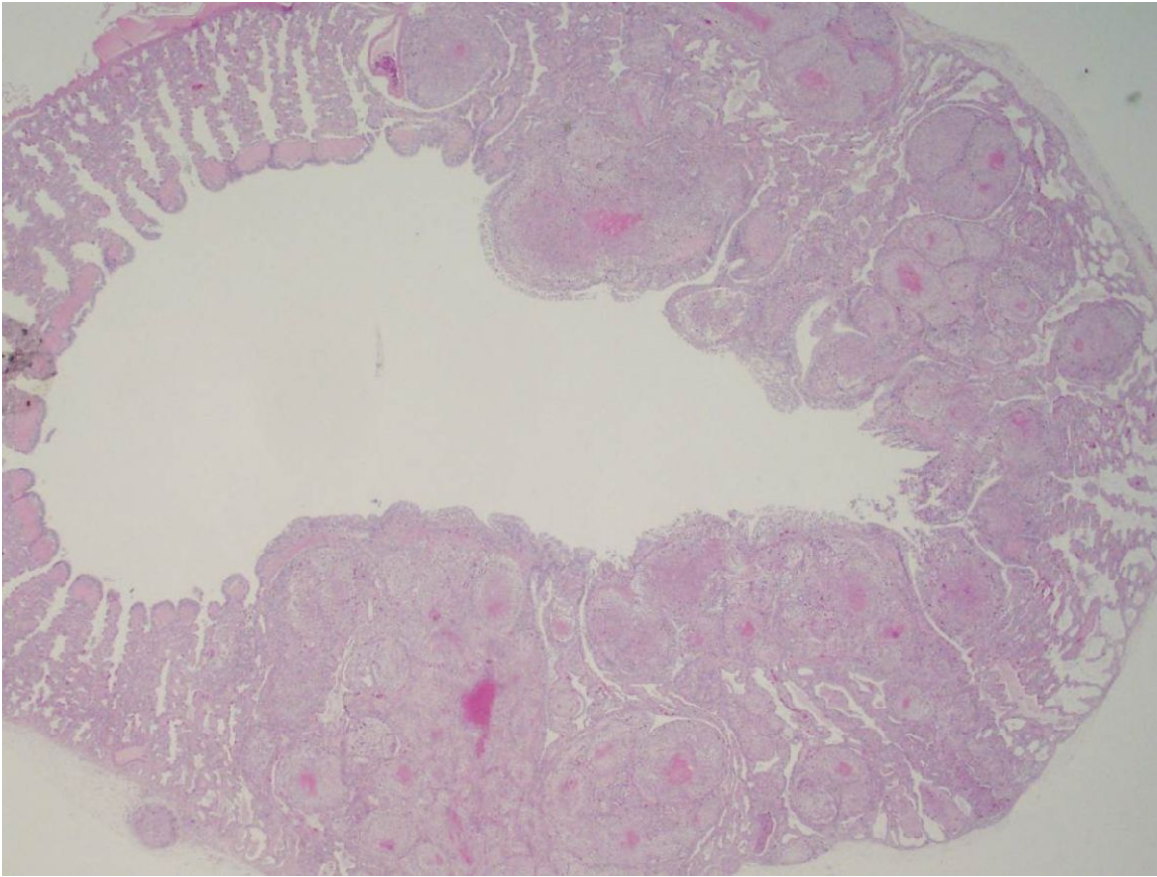
Below: Coiled nematode external to stomach.

**Histopathology:**

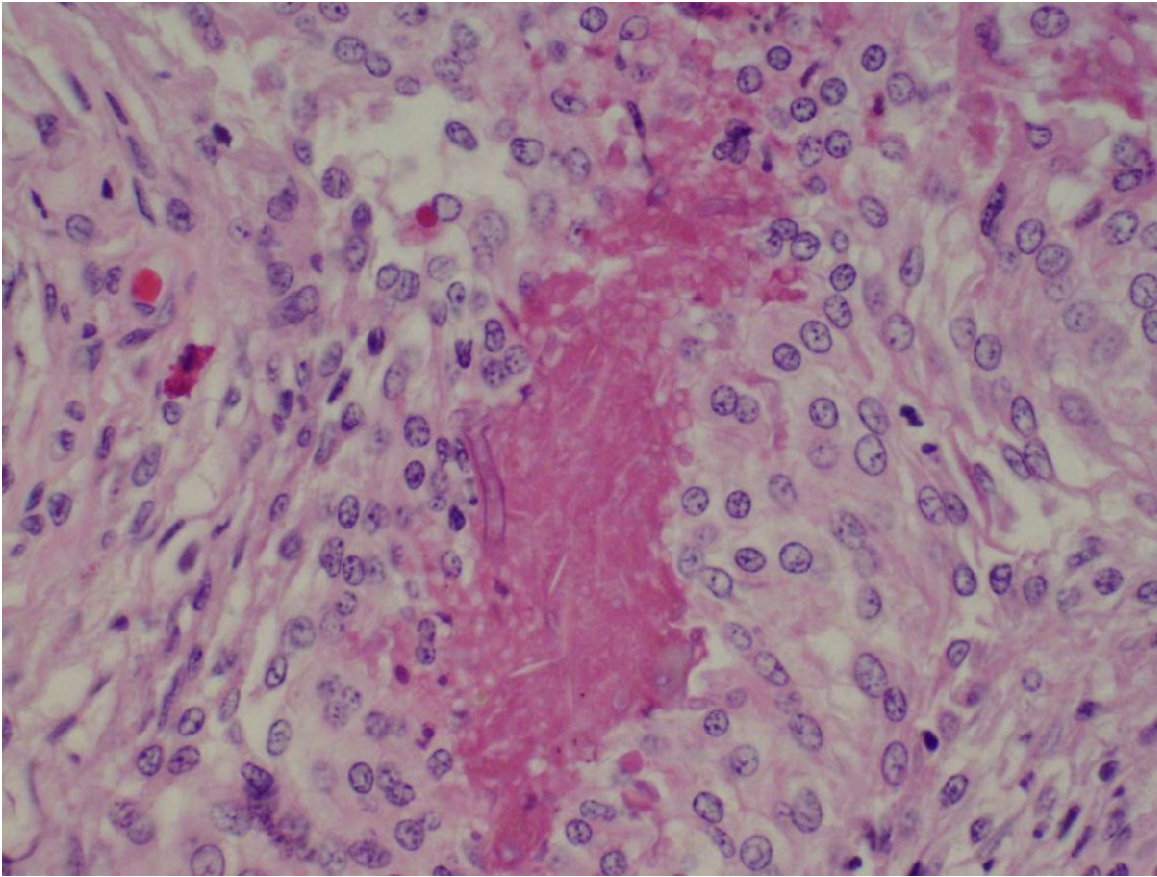
Lung: Faveolar septa are markedly expanded and distorted by multifocal to coalescing granulomas. These are characterized by central epithelioid to slightly foamy macrophages surrounding variable amounts of central eosinophilic debris.

Macrophages are variably surrounded by lymphocytes and fewer heterophils. Within this eosinophilic debris are multifocal fungal hyphae and spores. Hyphae are 4 to 6 µm diameter.

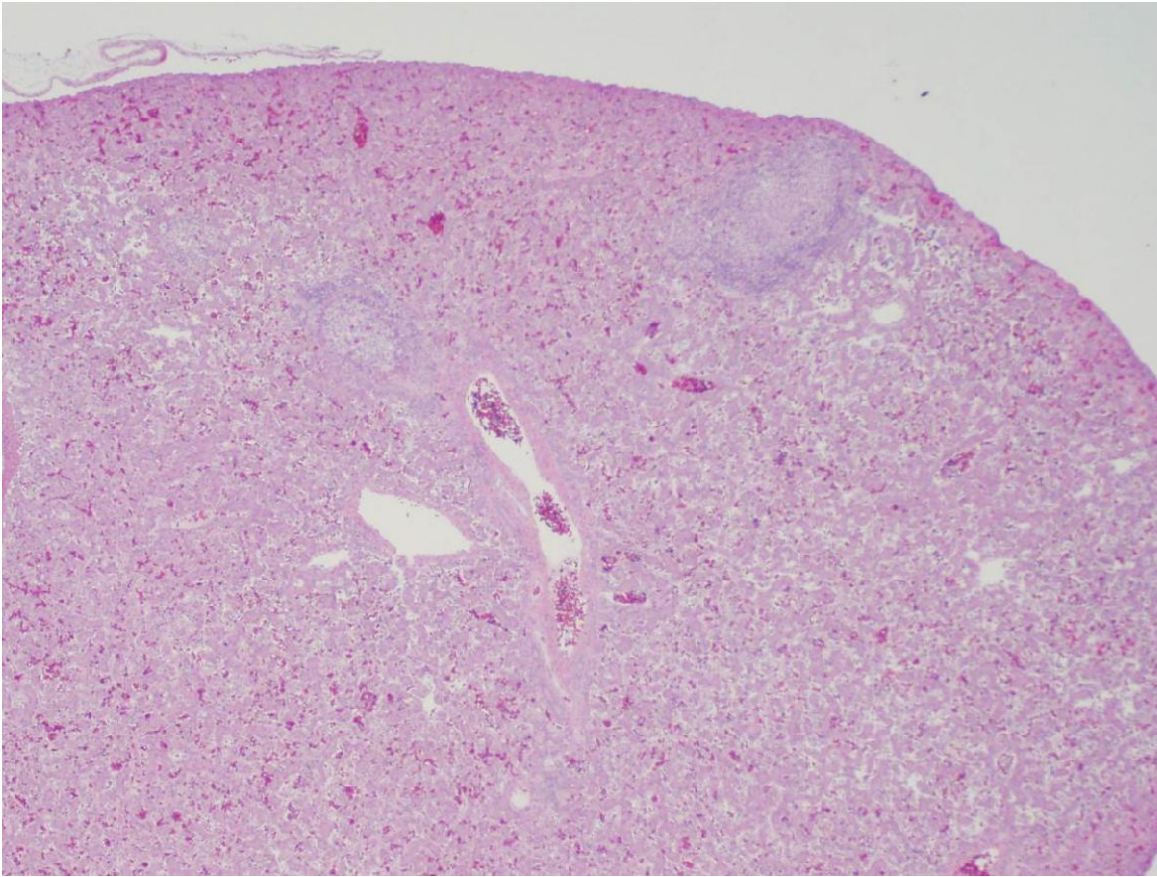
Below: Lung, 2X magnification, H&E. Faveolar septa on the left are normal, those on the right distorted by granulomas



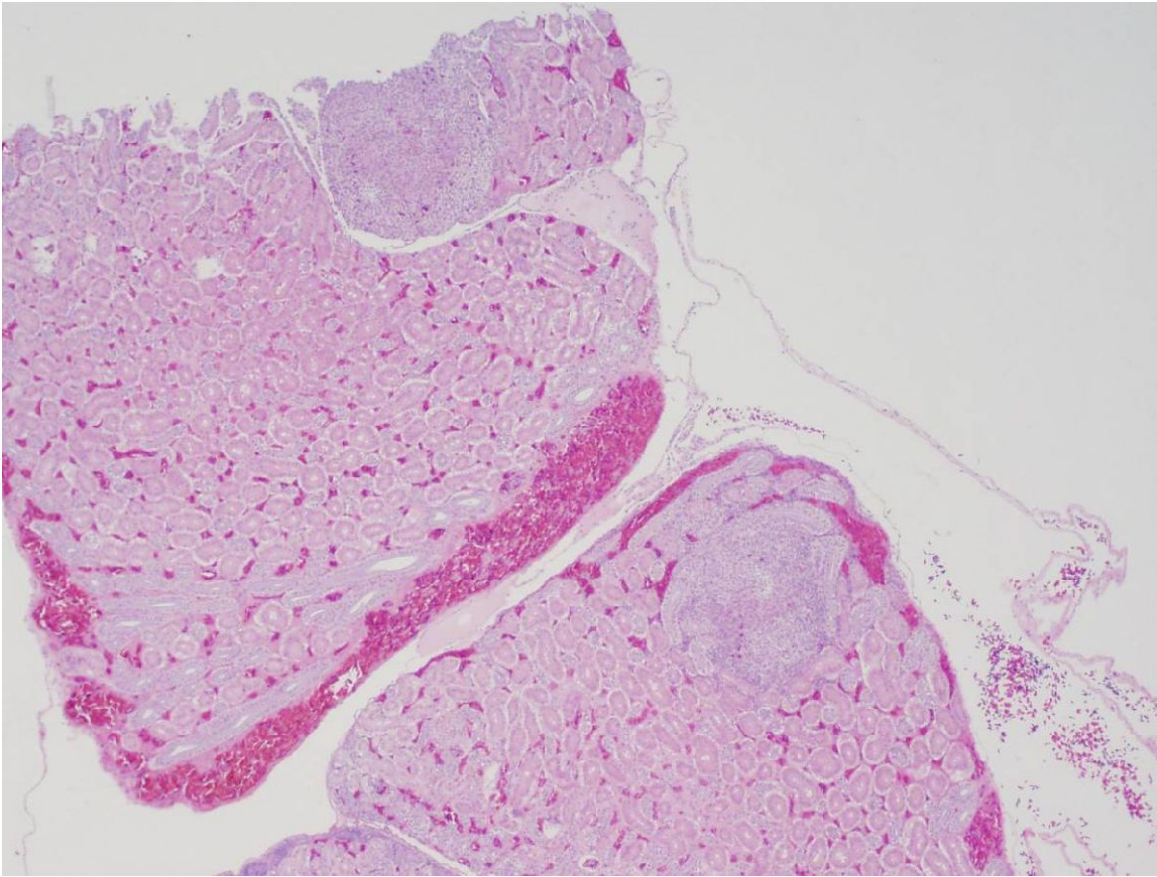
Below: Lung granuloma, 40X magnification, H&E. Fungal hyphae visible within eosinophilic debris.



Liver: There are multifocal granulomas with central macrophages surrounded by lymphocytes and plasma cells (photomicrograph, below). Hepatocytes along the margins of these granulomas are occasionally degenerate.

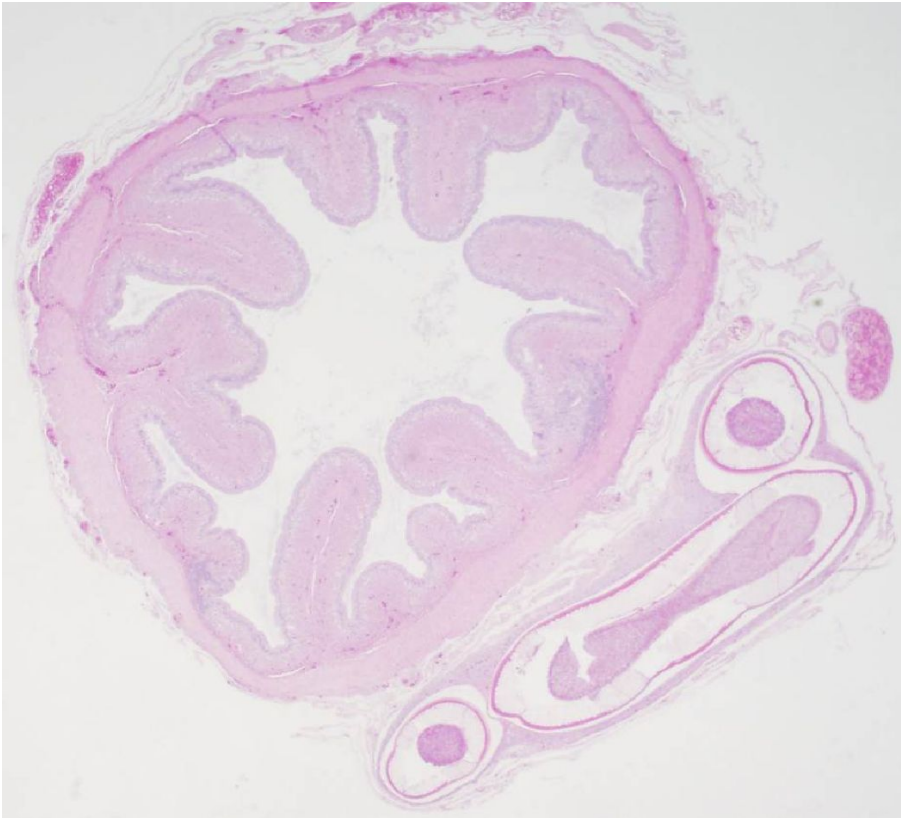


Kidney: There are multifocal granulomas similar to those described in the liver (photomicrograph, below). Within these are multifocal fungal hyphae.



Stomach: Within the serosa are few cross, longitudinal, and tangential sections of adult nematodes. These have a thin, very finely ridged cuticle and polymyarian, coelomyarian musculature. There are very prominent lateral cords. Narrowly surrounding these parasites are fibroblasts, macrophages, and fewer heterophils. Within the submucosa is a small aggregate of larval nematodes, approximate 70 μm in diameter, with large lateral cords and fine cuticular ridges. These are narrowly surrounded by macrophages, fibroblasts, rare heterophils and few lymphocytes.

Picture below: photomicrograph, 2X, H & E. Stomach on the left, nematodes in the lower right



Soft tissue of oral cavity: There is a longitudinal to tangential section of a nematode. There is a very thin cuticle, and inapparent musculature. Intestine is lined by large, few, uninucleate cells.

Heart, trachea, small intestine, eye, and colon: unremarkable.

Brain: *pending*

Laboratory Diagnosis:

- **Multisystemic fungal granulomas**
 - Lung
 - Liver
 - Kidney
- Nematodiasis

Comments:

- Over 60% of the lung parenchyma is effaced by these granulomas. Per a phone discussion with the owner, we will pursue both fungal culture, and, if possible, qPCR for *Ophidiomyces ophiodiicola*.
- I did not see any indication of chronic or previous skin infection of the head.
- I think the finding of nematodes is incidental. There may have been 2 species, one in the oral cavity and one in the stomach.
- Please correlate clinically and contact the laboratory if further testing is desired or questions arise.

Rachel J. Derscheid, DVM, PhD, DACVP

KEY: Tests: FA = Fluorescent Antibody, IHC = Immunohistochemistry, MALDI = Matrix-assisted laser desorption/ionization, MLV = Modified Live Virus, ORF = Open Reading Frame, PCR = Polymerase Chain Reaction, RFLP = Restriction Fragment Length Polymorphism, VI = Virus Isolation. Agents: BCV = Bovine Coronavirus, BRSV = Bovine Respiratory Syncytial Virus, BVDV = Bovine Viral Diarrhea Virus, CSF = Classical Swine Fever, HPS = *Haemophilus parasuis*, IAV = Influenza A Virus, IBRV = Infectious Bovine Rhinotracheitis Virus, MHP = *Mycoplasma hyopneumoniae*, MHR = *Mycoplasma hyorhinis*, MHS

= *Mycoplasma hyosynoviae*, PCV = Porcine Circovirus, PDCV = Porcine Deltacoronavirus, PEDV = Porcine Epidemic Diarrhea Virus, PPV = Porcine Parvovirus, PRCV = Porcine Respiratory Coronavirus, PRRSV = Porcine Reproductive & Respiratory Syndrome Virus, PRV = Pseudorabies Virus, SVA = Senecavirus A, TGEV = Transmissible Gastroenteritis Virus.

<u>Test Ordered</u>	Laboratory Result(s)		
	<u>Order Date</u>	<u>Current Status</u>	<u>Complete Date</u>
Necropsy (juvenile - adult)	3/21/2017	No Result	
Hematoxylin and Eosin Slides	3/21/2017	Result Released	3/22/2017

Histopathology

Hematoxylin and Eosin Slides

<u>Animal ID</u>	<u>Specimen</u>	<u>Slides</u>	<u>Comments</u>
A, Florida Water Snake	Assorted	3	